ASSESSMENT OF COMPUTED TOMOGRAPHIC UROGRAPHY IN THE DIAGNOSIS OF URINARY TRACT ABNORMALITIES IN A TERTIARY HOSPITAL.

[1]Danjem SM, [1]Salaam AJ,
[1]Department of Radiology, Jos University Teaching Hospital PMB 2076, Jos.

Correspondence:
Danjem Samuel Moses,
Email- samueljiblik@gmail.com, sdanjem@yahoo.com
Phone:+234806120600

ABSTRACT

Background
Computed Tomographic urography (CTU or CT urography) is essentially defined as a Computed tomographic (CT) examination of the urinary tract before and after the administration of intravenous contrast material that includes excretory phase images. The aim of this study was to evaluate the use of CT urography and to document the different urologic pathologies seen on CT urography in our hospital.

Methods
This is a retrospective hospital based study of patients who had CT urography from September 2013 to June 2015. The CTU images obtained from this period were retrieved and evaluated. The data was subjected to statistical analysis.

Results
The CTU of 160 patients were analyzed. Mean age of the study was 40.3±16.9 (range, 2-82 years). 80.5 (50.3%) were females while 79.5 (49.7%) were males.
The commonest clinical indication for CTU was hydronephrosis (25.4%), while the least indication was renal tuberculosis (0.6%).
24 (38.4%) cases were normal, 136 (61.6%) revealed positive findings. Common pathologies were calculi 25.9%, obstructive uropathies 24.2%.

Conclusion
CT urography has earned a pivotal place in the evaluation of urinary tract evaluation because of its high sensitivity in this regard.

Key Words: *CT urography; urinary tract abnormalities.*

INTRODUCTION

Imaging has a vital role to play in the management of uropathies which often present in different ways. Indications for imaging the urinary tract continue to evolve. Conditions commonly referred for radiological evaluation include urinary calculus disease, hematuria, flank and abdominal pain, suspected renal or urothelial neoplasm, a variety of inflammatory conditions, and congenital anomalies of the kidneys and ureters.[1]

Intravenous urography (IVU) has long been the major and first-line modality in evaluating urinary tract abnormalities. However, the imaging findings are prone to be affected by artifacts such as bowel gas, bowel content or even processing artifacts, and poor or non-opacified urinary tract due to impaired renal function).[2,3] Technologic advances in both computed tomography (CT) and magnetic resonance (MR) imaging have resulted in the ability to image the urinary tract in ways that surpass the prior mainstay of urinary tract imaging, the intravenous urogram.[4]

The advances in the past decade in using CT scan to diagnose nephrolithiasis, along with progress in developing multidetector CT (MDCT) and 3D reconstruction, have revolutionized the value of CT in urology. In many institutions, CT has replaced intravenous (IV) pyelograms. CT scans performed dynamically through the unenhanced, nephrographic, and excretory phases may replace other imaging tests to evaluate hematuria. Staging of

urologic malignancies includes a CT scan of the abdomen. Preoperative planning for living related kidney donors using CT angiograms has become common practice in transplant centers. Additionally, the widespread use of CT in evaluating abdominal pain has led to an increase in diagnosis of incidental urologic findings.[5]

CT urography is essentially defined as a CT examination of the urinary tract before and after the administration of intravenous contrast material that includes excretory phase images. Despite the acceptance of this new use of CT, there is no universally accepted technique for performing CT urography. An un-enhanced CT scan is obtained to detect calculi, reveal the unenhanced appearance of masses (throughout the urinary tract), and provide a baseline attenuation value to calculate enhancement of masses and other abnormalities. Unenhanced images are also useful for evaluating masses for fat or calcium. Enhanced images (by using intravenous contrast material that contains 30–42 g of iodine) are an important component of CT urography; these images increase the sensitivity for detecting virtually all urologic abnormalities (except stones and calcifications) and are used to detect the presence of enhancement in a mass, particularly renal masses. To optimize both detection and characterization, renal masses are best examined during the nephrographic phase (when both the renal cortex and the medulla are enhanced) that occurs approximately 100 seconds after intravenous administration of 100–150 mL of contrast material (300 mg of iodine per milliliter).[6-9]

There are various documentations on the findings of CTU mostly from developed countries[1,10,11,12] with relatively scanty reports from developing countries.

CT urography for patients who had clinical symptoms that highly suggested urinary tract abnormalities as well as the diagnostic value of CT urography were evaluated with the aim of documenting the different urologic pathologies seen in Jos University Teaching Hospital.

METHODS

This was a retrospective descriptive hospital based study which was approved by the Ethical Committee of the hospital. Patients who had CTU between September 2013 and June 2015 were identified from our CT achieves. The CT images were reviewed and 160 consecutive patients who had non-enhanced and excretory phase CT for evaluating urinary system were selected. Women who were pregnant were excluded from the study.

Patients were examined using a 4-slice CT scanner Bright Speed GE (General Electric) Medical Systems (USA). CT scans were obtained from the kidneys to the bladder with the following technique: a collimator of 5mm, a pitch of 6, and with 200 mAs. Images were reconstructed at a thickness of 2.5 mm with intervals of 1.25mm. Three-dimensional (3D) reconstructions of the nonenhanced and contrast-enhanced CT images were performed on the console. 3D reconstructions in coronal and sagittal projections were created with multiple planar reconstructions (MPR). The data generated were analyzed using SPSS version 20. Pearson correlation was performed and the level of significance set at 0.05. T-test was also performed to compare the different CTU findings with ages and sexes. The results were presented in form of tables, figure and chart.

RESULTS

The CTU of 160 patients were evaluated and analyzed. The patient's age range was from 2 to 82 years with a mean age of 40.3±16.9 years. The 31-40 age groups made up the largest group (22.6%) of the study population with least in the 61-70 age groups (5.0%) [Table 1].

80.5 (50.31%) were females while 79.5 (49.69%) were males (Figure 1).

The commonest indication was hydronephrosis 42 cases (25.4%), followed by renal calculi 34 (20.6%), flank pain 29 (17.4%), and bladder mass 11 (6.6%), while the least indications were renal TB 1(0.6%) and nephrocalcinosis 1(0.6%).

CT urographies were essentially normal in 24 (38.4%) of the study population while 136 (61.6%) revealed positive findings, Table 3. Of the positive findings, 52 cases (24.2%) were obstructive uropathies (due to pelvi-ureteric junction obstruction, aberrant vessels, ureteric calculi, post operation, prostate enlargement etc), while 56 (25.9%) were cases of urinary tract calculi and 49 (22.6%) cases of urinary tract masses. Fourteen (6.5%) cases of congenital anomalies, 6 (2.8%) cases of non-functional kidneys, 4 (1.9%) cases of renal trauma. 2 (0.9%) Nephrocalcinosis, 2 (0.9%) Schistosomiasis, and 1 (0.5%) Bladder diverticulum were the least findings seen.

DISCUSSION

Imaging the urinary tract is taking a pivotal role not only in making diagnosis but also for interventional purposes. CT has established its role in this perspective. Because of the good imaging resolution and rapid examination time of helical CT scan, it has become a promising modality for diagnosing urinary tract abnormalities. By improvement of the computer technique, 3D CT urography reformatted from axial

thin-cut multi-slice CT imaging is capable of providing more diagnostic information than that by conventional CT.[13] The radiation dose is also markedly reduced by using the design of multiple-detector of helical CT scan. Recent study showed that the radiation dose of CT urography was similar or just slightly greater than that of IVU.[14] Magnetic resonance imaging (MRI) is also assuming a promising role in the imaging the urinary tract. Other modalities include Ultrasonography, IVU, Scintigraphy, positron emission tomography (PET), single photon emission computed tomography (SPECT) and angiography. In our centre, CTU, IVU and ultrasonography are the available modalities that are used to evaluate the urinary tract.

In our 160 patients with clinical manifestations of urinary tract disorders that had CTU, there were more women than men. This possibly could be due to the fact that more women seek medical attention than men in this part of the world. In contrast to our study, Meenakumari *et al*[10] recorded more men with obstructive uropathy than females patients. Patients from the age group 31-40 years had more CTU than any age group. This is different from other studies which documented the age group 41-50 years having more CTU[10] and MRI for obstructive uropathies[15].

Hydronephrosis was the commonest indication in our study (25.4%) closely followed by renal calculi (20.6%) and Flank pain (17.4%). This is in agreement with Skip *et al*[1]. The least indications was nephrocalcinosis (0.6%). This probably is due to the fact that this anomaly is rare in our environment.

Findings from CTU could be positive or negative. The positive findings could range from non-malignant to malignant conditions of the urinary tract or effect of pathologies from adjacent structures. Out of the 160 patients that had CTU for clinical signs and symptoms of urinary tract disease, 24 cases (38.4%) had normal (negative) findings while 136 cases (61.6%) had abnormalities (positive findings). The normal findings in 39.4% of cases could possibly be due to the following reasons; Inappropriate clinical history because some conditions like muscle cram could present as flank pain mimicking renal calculi or inflammatory condition such as pyelonephritis and the patient could be referred for CTU and hence a negative CTU finding; Pitfalls of CT technique. CT is limited with regard to detection of pyelonephritis, though the diagnosis can be suggested if the clinical history is appropriate and findings such as perinephric stranding, renal enlargement and possibly hydronephrosis are present.[16] The abnormalities detected in 61.6% of the population in this study support the high sensitivity of CTU in detection of urinary tract disorders.[11,12] In this group of patients, the commonest findings was urinary tract calculi constituting 56 cases (including 30 cases of renal calculi, 24 cases of ureteric calculi and 2 cases of urinary bladder calculi) [Fig. 2]. This support the fact that urinary calculi are common in our environment as it is elsewhere[17,18] and also due to the fact that CT is highly sensitive in detecting urinary tract calculi.[4,11,12] Obstructive uropathy was noted in 24.2% of cases with definition of the causes. This finding is in consonant with other studies.[10,12] 49 cases of urinary tract masses were seen some with classical features of malignancy (consisting of 10 cases of bladder masses with malignant features, 39 cases of both cystic and solid renal masses) {Fig.3}. We also detected 14 congenital urinary abnormalities (including 5 cases of ectopic kidney, 4 cases of duplication of the ureters, 2 cases of hypoplastic kidney, 4(1.8%) cases of polycystic kidneys(Fig. 4) , 1 Horse-shoe kidney, 1 rotated kidney and 1 renal agenesis). We found that CT urography was effective in diagnosing these congenital disorders; the same conclusion was also made elsewhere.[11,19] We noted 6 cases of unilateral non-functional kidney. Other least common conditions which include three renal trauma, two Schistosomiasis, two nephrocalcinosis, one suprarenal mass, and one bladder diverticulum were also documented.

Table 1: Age distribution pattern

Age group	Frequency	Percentage (%)
[illegible]	19	11.9
21-30	32	20.1
31-40	36	22.6
41-50	34	21.4
51-60	22	13.2
61-70	8	5.0
>70	9	5.7
Total	160	100.0

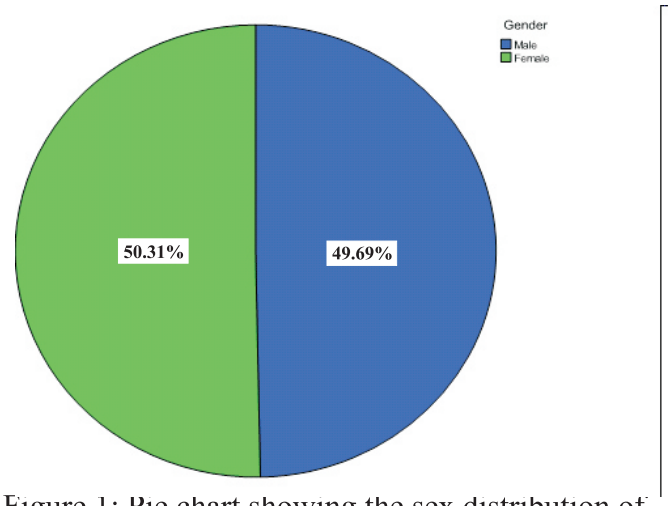

Figure 1: Pie chart showing the sex distribution of the patients.

Table 2: Showing the distribution pattern of Indication for CTU

Indications	Frequency	Percentage
Renal calculi	34	20.6
Bladder mass	11	6.6
Suprarenal mass	3	1.8
Intra-abdominal mass	3	1.8
Renovascular HTN	5	3.0
Hematuria	2	1.2
Renal atresia	1	0.6
Flank pain	29	17.4
Hydronephrosis	42	25.4
Polycystic kidneys	5	3.0
Renal mass	9	5.4
Renal trauma	3	1.8
Ectopic kidney	2	1.2
Pyelonephritis	3	1.8
Nephrocalcinosis	1	0.6
Renal TB	1	0.6
Prostate enlargement	3	1.8
Renal cyst	9	5.4
Total	166	100

Table 3: Distribution pattern of CTU finding

Findings	Frequency	Percent
Normal	24	11.1
Urinary tract calculi	56	25.9
Urinary tract mass	49	22.6
Congenital abnormality	14	6.5
Non function kidney	6	2.8
Renal trauma	3	1.4
Obstructive uropathy	52	24.2
Polycystic kidney dx	4	1.9
Uterine mass	2	0.9
Schistosomiasis	2	0.9
Nephrocalcinosis	2	0.9
Suprarenal mass	1	0.5
Bladder diverticulum	1	0.5
Total	216	100.0

Note: Some patients have multiple indications

Fig. 2: Axial CT native scan demonstrating a hyper dense focus
(calculus) within the bladder.

Fig.3; Coronal reformatted CTU image showing a hypodense bladder mass with irregular outline.

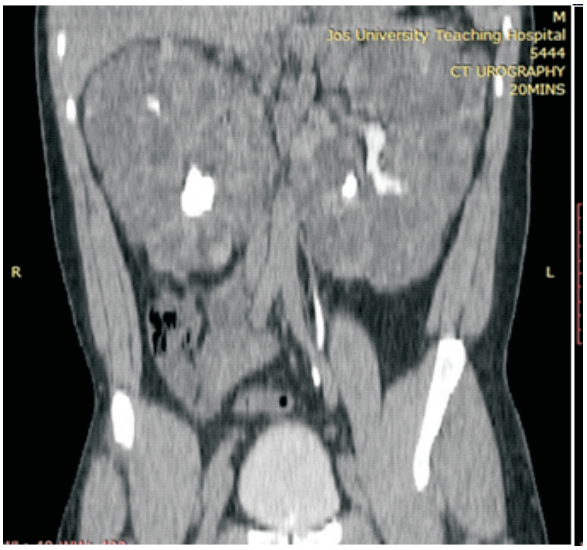

Figure 4: Coronal CTU image showing multiple Cysts in both kidneys consistent with polycystic Kidney.

CONCLUSION

CT urography is a modality for evaluating urinary tract abnormalities. Our results show that CT urography is exceptional in diagnosing urinary tract abnormalities, especially in urolithiasis. It also can provide more information on the non-urinary tract abnormality of the patients. Considering the diagnostic value and immediate proper management for patients with urinary tract disorders, CT urography has earned a pivotal place in the evaluation of urinary tract evaluation.

REFERENCES

1. Skip M. A, Susan H, and Nicholas P. CT urography: Review of technique and spectrum of diseases. www.appliedradiology.com; 2011. Acessed on18/12/2015
2. Niall O, Russell J, MacGregor R, Duncan H, Mullins J. A comparison of non-contrast computerized tomography with excretory urography in the assessment of acute flank pain. J Urol 1999;161:534-7.
3. Hamm M, Wawroschek F, Weckermann D, Knopfle E, Hackel T, Hauser H, et al. Unenhanced helical computed tomography in the evaluation of acute flank pain. Eur Urol 2001;39:460-5.
4. Stuart G.S, John R.L, Stephen E.A. What Is the Current Role of CT Urography and MR Urography in the Evaluation of the Urinary Tract? Radiology 2009:250;309-323.
5. Fadi NJ, David MK, Richard DW. Maximizing Clinical Information Obtained by CT. In Urol Clin N Am. 3006;33:287-300.
6. Bosniak MA. The small (less than or equal to 3.0 cm) renal parenchymal tumor: detection, diagnosis, and controversies. Radiology 1991;179:307–317.
7. Silverman SG, Lee BY, Seltzer SE, Bloom DA, Corless CL, Adams DF. Small (=3 cm) renal masses: correlation of spiral CT features and pathologic findings. AJR Am J Roentgenol 1994;163:597–605.
8. Akbar SA, Mortele KJ, Baeyens K, Kekelidze M, Silverman SG. Multidetector CT urography: techniques, clinical applications, and pitfalls. Semin Ultrasound CT MR 2004;25:41–54.
9. Cohan RH, Sherman LS, Korobkin M, Bass JC, Francis IR. Renal masses: assessment of corticomedullary-phase and nephrographic-phase CT scans. Radiology 1995;196:445–451.
10. Meenakumari A, Tseizo K, Kaku S. Evaluation of Obstructive Uropathy with Computed Tomography Urography and Magnetic Resonance Urography - A Clinicoradiological study. IOSR Journal of Dental and Medical Sciences. 2015;14:1-5.
11. Wen-Chiung L, Jia-Hwia W, Chao-Jun W, Cheng-Yen C. Assessment of CT Urography in the Diagnosis of Urinary Tract Abnormalities. J Chin. Med. Assoc 2004;67:73-78
12. Olivera N, Sanja S, Viktor T, Marijana BN, Kosta P, Viktorija VĆ. Multislice computed tomography urography in the diagnosis of urinary tract diseases. Vojnosanit Pregl 2011; 68:417–422.
13. Van Beers BE, Dechambre S, Hulcelle P, Materne R, Jamart J. Value of multislice helical CT scans and maximum-intensityprojection images to improve detection of ureteral stones at abdominal radiography. Am J Roentgenol 2001;177:1117-21.
14. Caoili EM, Cohan RH, Korobkin M, Platt JF, Francis IR, Faerber GJ, et al. Urinary tract abnormalities: initial experience with multi-detector row CT urography. Radiology 2002; 222:353-60.
15. Bozgeyik Z, Kocakoc E, Sonmezgoz F.

Diffusion-weighted MR imaging findings of kidneys in patients with early phase of obstruction. Eur. J. Radiol. 2009;70:138–41.
16. Eric PT, Paul MS, William PS. Evaluation of the Patient with Flank Pain and Possible Ureteral Calculus. Radiology 2003;228:319–329.
17. Chand RB, Shah AK, Pant DK and Paudel S. Common site of urinary calculi in kidney, ureter and bladder region Nepal Med. Coll. J 2013;15: 5-7
18. Stamatelou KK, Francis ME, Jones CA et al. Time trends in reported prevalence of kidney stones in the United States:1976–1994. Kidney Int'l 2003;63:1817-23.
19. Kim JK, Cho KS. Pictorial review: CT urography and virtual endoscopy: promising imaging modalities for urinary tract evaluation. Br J Radiol 2003;76:199-209.